

MEIASTINOSCOPY

BY DR MONTAZER

Mediastinoscopy

- Mediastinoscopy remains one of the most common operations performed by most general thoracic surgeons.
- In 1954 Harken and associates first published a way to explore the superior mediastinum from a lateral approach after excision of the scalene fat pad.

Indications

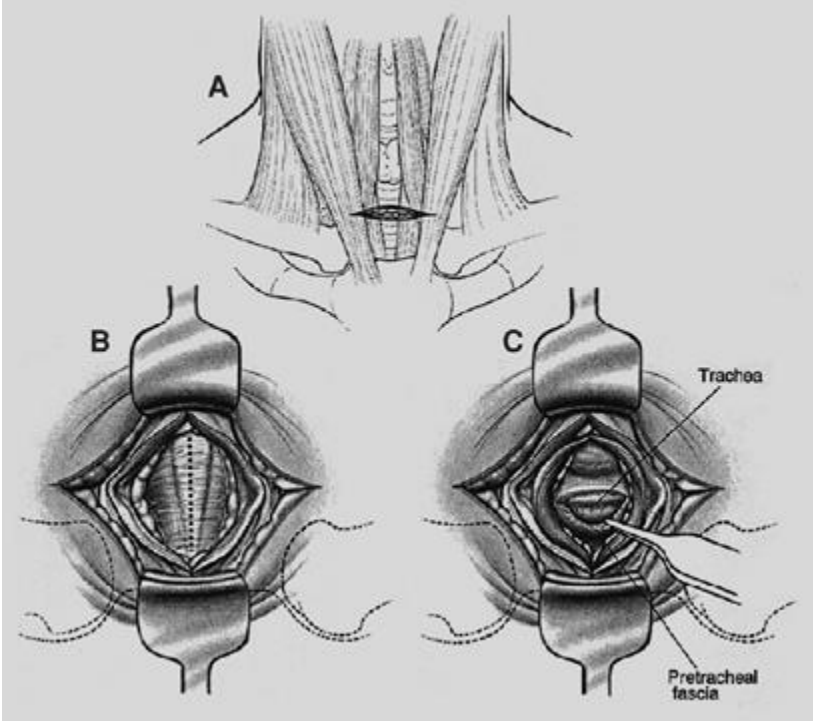
- The most common indication for mediastinoscopy is staging and diagnosis of lung cancer.
- diagnosing other mediastinal diseases is valuable but less frequent.
- differentiating benign from malignant lymph nodes
- With improvement in the resolution of CT scanning and the addition of PET scanning, mediastinoscopy is being used more selectively.
-

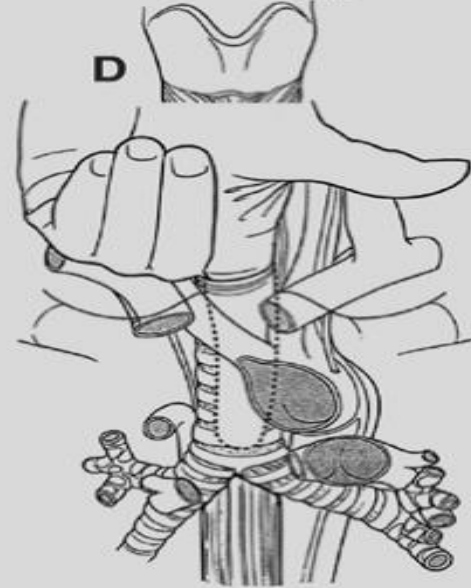
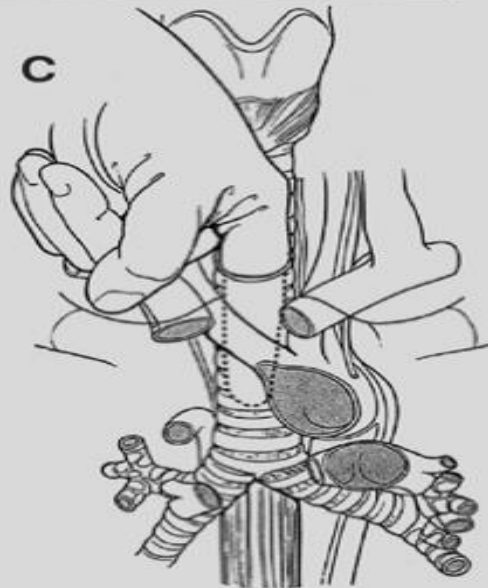
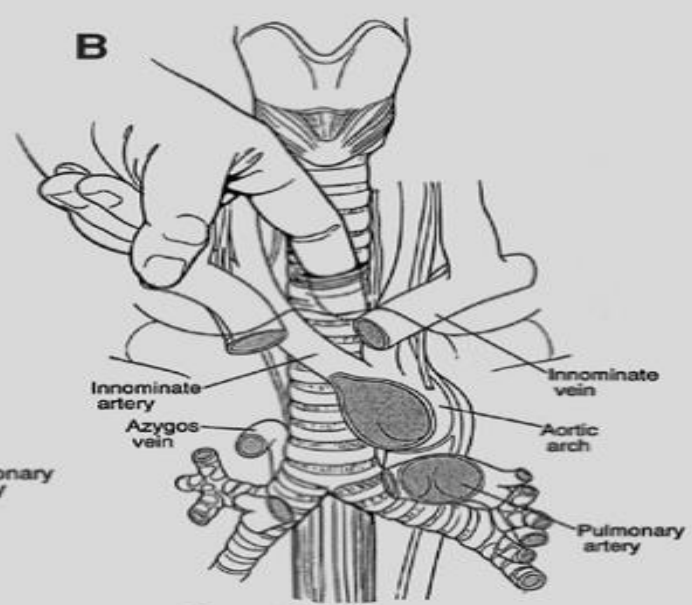
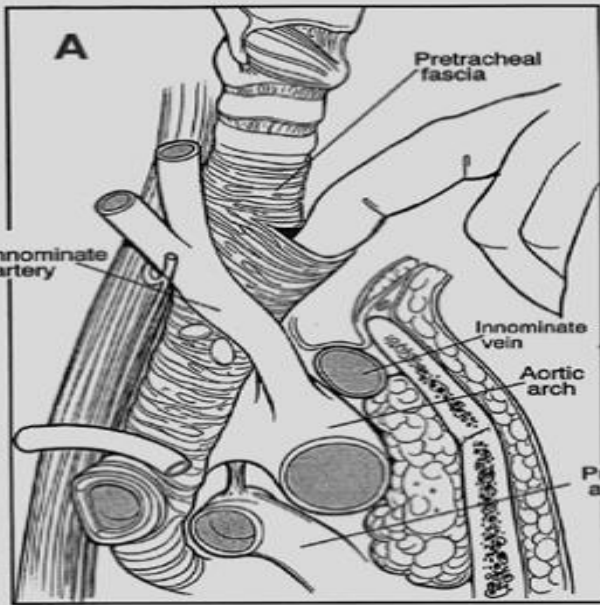
- false-negative PET results will occur in only about 5% of cases, whereas the false-negative rate of mediastinoscopy is approximately 10%.
PET positivity

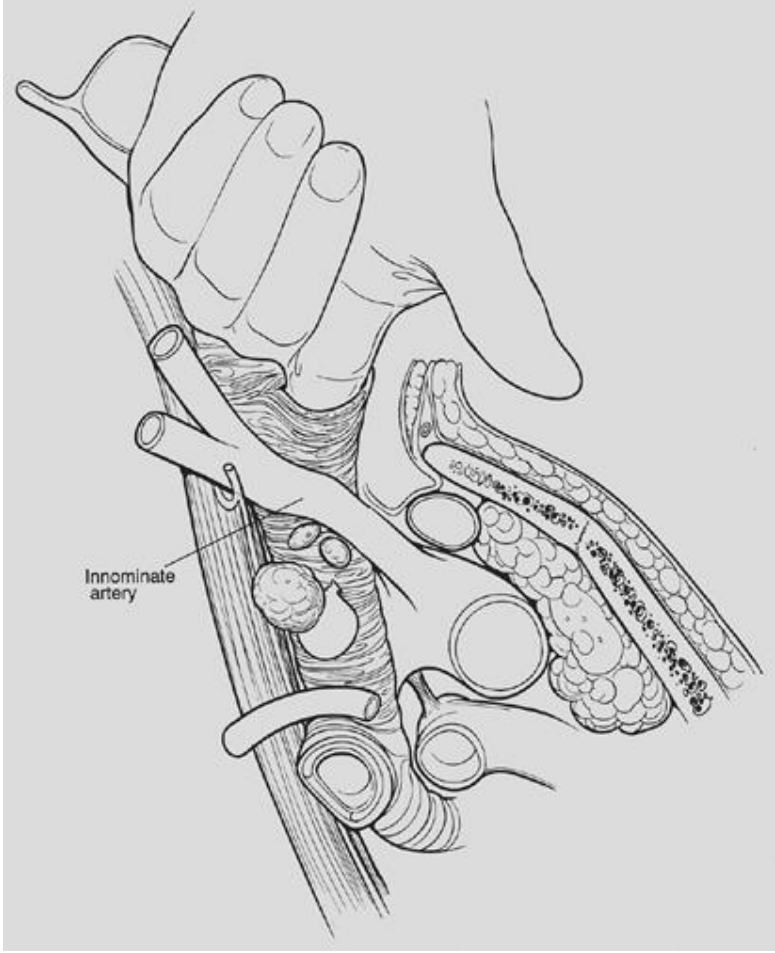
- **Contraindications and Cautions**
- Associated conditions that preclude safe mediastinoscopy include huge cervical goiter, extensive calcification or aneurysm of the innominate artery, and permanent tracheostomy after laryngectomy and radiation.

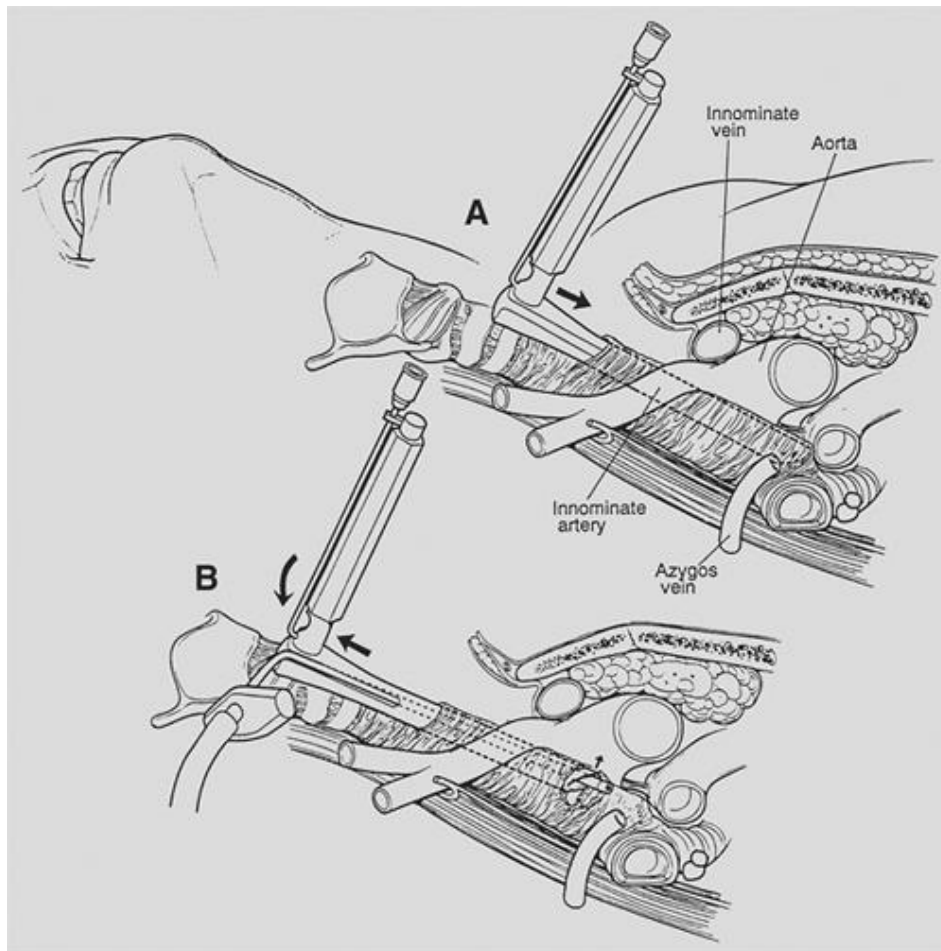
several other factors may increase the difficulty of mediastinoscopy

- . A carotid bruit, especially on the right
- Prior sternotomy or neck incision
- Prior mediastinoscopy.
- Repeat mediastinoscopy is nevertheless feasible in most cases and has been reported to be safe even in the setting of induction chemotherapy









Complications

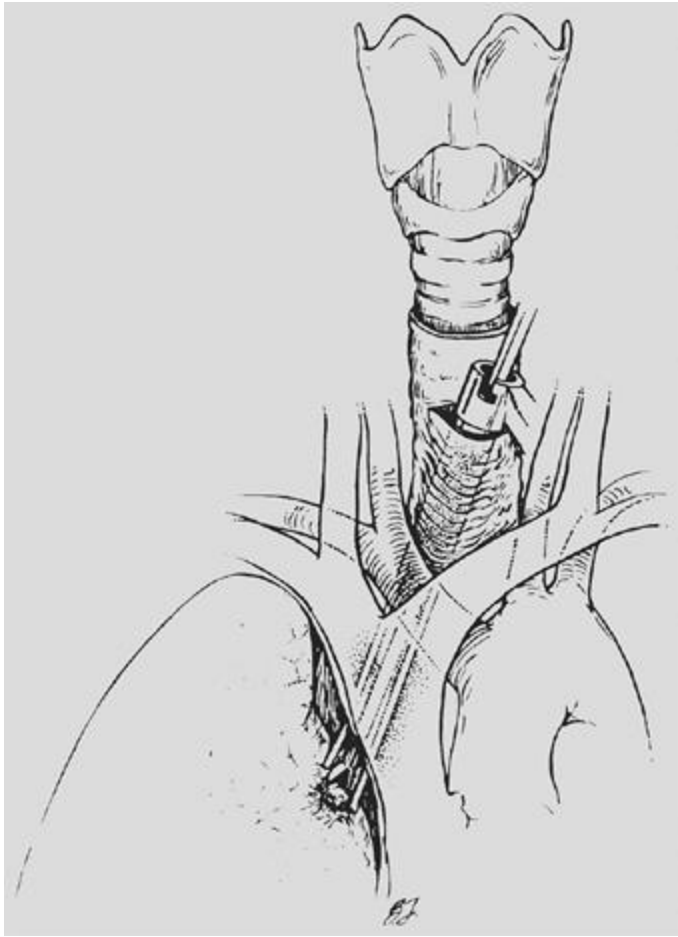
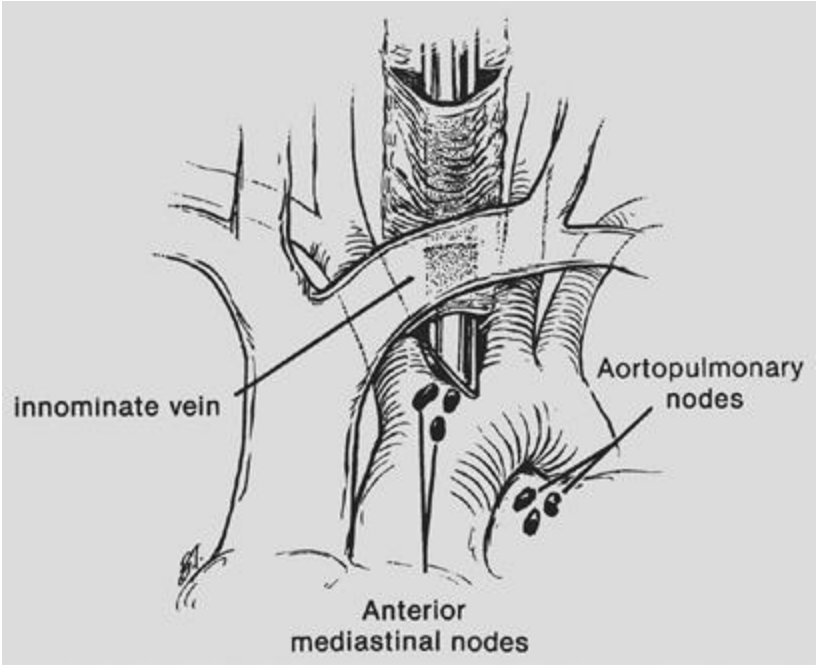
- Mediastinoscopy is a safe procedure in experienced hands .
- The mortality 0% to 0.08%.
- Complications occur in up to 3% , major in 0.5% or less.
- The most common complications :vocal cord dysfunction (0.55%), hemorrhage (0.32%), tracheal injury (0.09%), and pneumothorax (0.09%).

The most feared complication

- Massive hemorrhage from damage to the aortic arch or its branches, superior vena cava, azygos vein, or pulmonary artery.

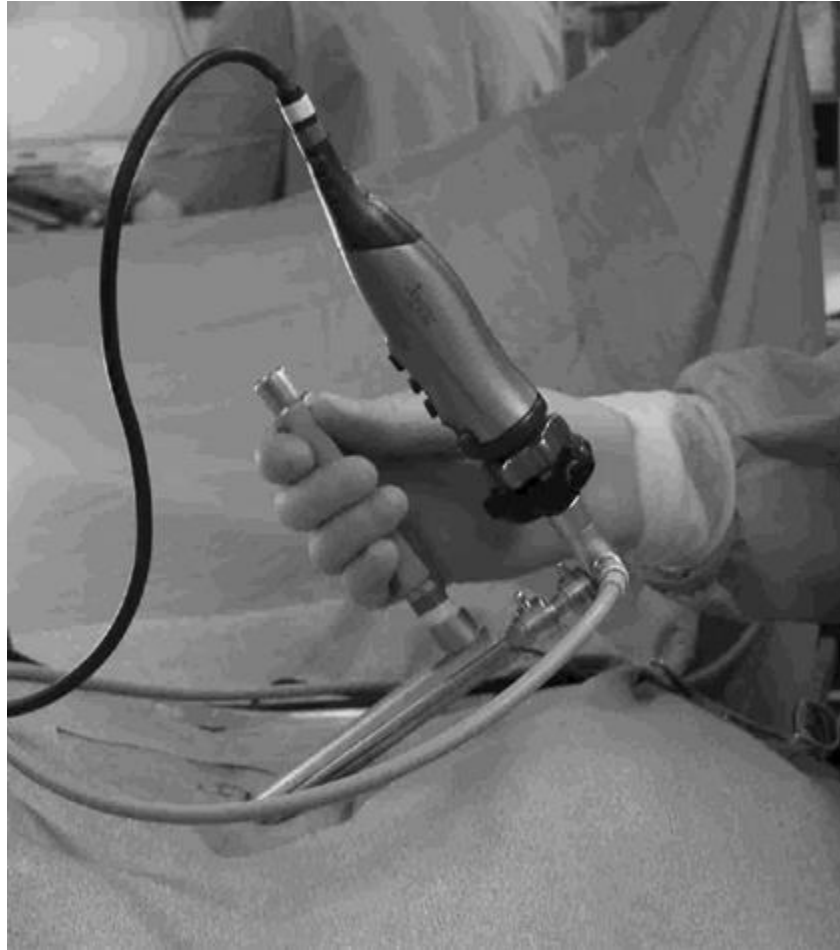Mediastinopleuroscopy

- In mediastinopleuroscopy the pleural space is intentionally entered .
- On the right, the pleura is opened posterior to the innominate artery, whereas on the left, entry is gained between the left common carotid and left subclavian arteries.
- : pleural biopsy and fluid sampling, small upper-lobe lung biopsies
- the risk of seeding a clean mediastinum by transpleural biopsy of an upper-lobe cancer or infection.



Video-Assisted Mediastinoscopy and Mediastinoscopic Lymphadenectomy

- Standard mediastinoscopy provides visualization of the pretracheal space and access to the mediastinal lymph node packets, but it provides limited view owing to the small caliber of the scope.
- The surgeon can then direct the scope, dissect the tissues using the suction cautery, and perform lymph node biopsies guided by the video image.

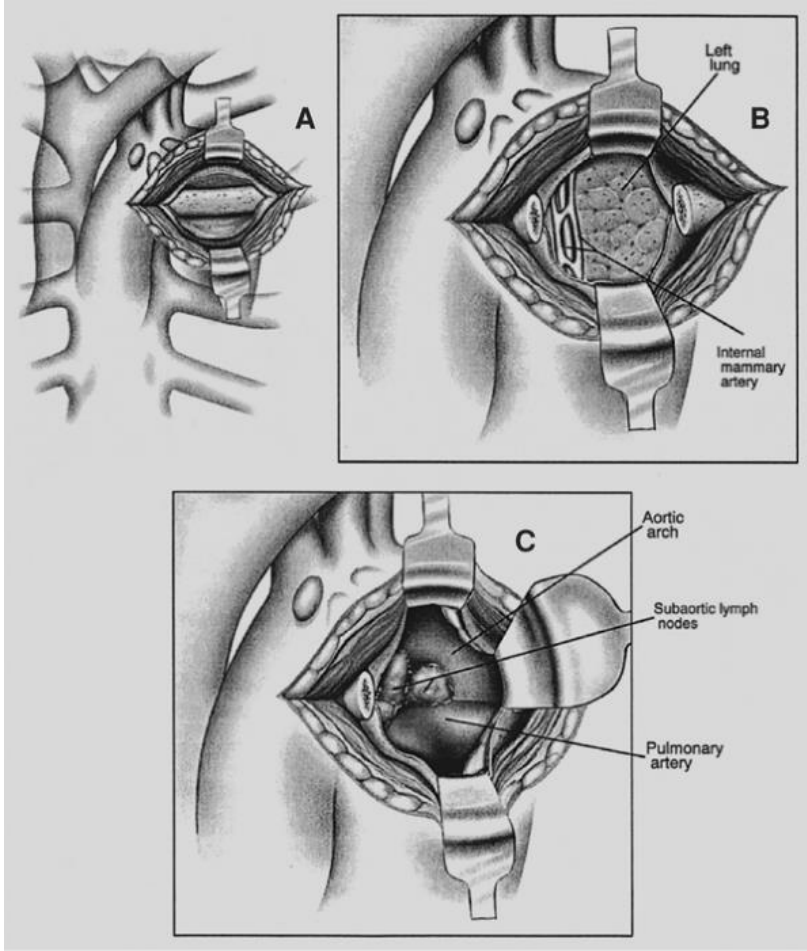


Anterior Mediastinoscopy and Anterior Mediastinotomy

- Anterior or parasternal mediastinotomy in 1966 as a means of accessing the nodes not reached by cervical mediastinoscopy in the subaortic region.
-
- This approach can also be used on the right and offers access to the upper hilum, lung, and pleura on both sides
- *:lung cancer, anterior mediastinal masses.

anterior mediastinoscopy

- refers to the common modification of the original operation in which there is no removal of a costal cartilage and a mediastinoscope is passed through a small incision in the second intercostal space.



- ***The End***