Esophageal Cancer: Introduction

The incidence of esophageal cancer is on the rise with over 12,000 Americans developing this disease each year (Figure 2). Variations in the incidence of esophageal cancer are seen with age, sex, and race. Advances in medical and surgical therapy have led to improvement in the survival rates but continued improvement in survival is dependent on a better understanding of the relationship between environmental factors and the disease itself.

The incidence of esophageal cancer fluctuates dramatically throughout various regions of the world and has the largest variability of any known malignacy. High rates are found in people living in northeast China to north central Asia, Afghanistan and northern Iran. Other high-risk groups include the white population in parts of South Africa and areas of Finland, Iceland, and France. In the United States, trends demonstrate that black men have a fourfold greater incidence than white men for squamous cell esophageal cancer with significant variation in locale, nutritional status, socioeconomic status, and alcohol and cigarette use.

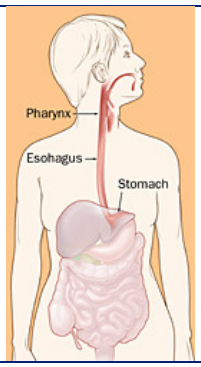

Figure 1. Location of the esophagus in the body.

What is Esophageal Cancer?

Esophageal cancer may be classified according to the site of origin. The malignancy may originate in the squamous cells, or in the columnar cells that line the esophageal lumen. Squamous cell carcinoma may occur throughout the length of the esophagus, whereas adenocarcinoma generally occurs just above the esophagogastric junction (Figure 3).

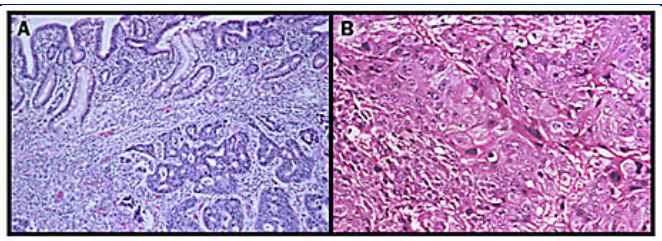

Figure 3. Histology; A, adenocarcinoma; B, squamous cell carcinoma

Symptoms

Early stage esophageal cancer may be totally asymptomatic or may present with mild nonspecific symptoms such as heartburn, atypical chest pain, or dyspepsia. Alternatively, patients may present with symptoms such as occult blood in the stool or iron deficiency anemia. Patients may report mild or intermittent dysphagia, odynophagia, or a foreign body sensation. These symptoms generally warrant diagnostic evaluation, including an esophagogastroduodenoscopy (EGD) (upper endoscopy), including diagnostic mucosal biopsy. Some early cancers are diagnosed during routine upper endoscopic surveillance for Barrett's esophagus. The symptoms of esophageal cancer generally progress rapidly. Symptoms of advanced esophageal carcinoma become apparent with tumor growth. An initial inability to swallow solids is followed by difficulty in swallowing ground food and finally liquids. Progressive dysphagia is the most common complaint in most patients (90%) with greater than 50% luminal occlusion or where luminal diameter is less than 13 mm.

Weight loss and anorexia are often present in patients with more advanced disease (due to inadequate intake of food secondary to dysphagia, or to a nonspecific effect of the cancer), predisposing the patient to nutritional deficits. Odynophagia occurs in about one half of the patients. Esophageal obstruction may cause aspiration of food and pneumonia. Tumor extension to the pericardium or mediastinum may cause retrosternal or back pain, as well as abscess formation. Hoarseness is usually associated with recurrent laryngeal nerve paralysis. Hiccups may occur due to mediastinal and/or diaphragmatic involvement of the tumor. Anemia and/or gastrointestinal bleeding and weakness may be present if the tumor is ulcerated and friable. Incessant cough and pneumonia should alert the clinician to the possibility of a tracheo- or bronchio-esophageal fistula resulting from tumor invasion of the nearby airways.

© Copyright 2001-2013 | All Rights Reserved.
600 North Wolfe Street, Baltimore, Maryland 21287

Esophageal Cancer: Anatomy

Anatomy

The esophagus serves as a conduit between the pharynx and the stomach (Figure 4). The body of the esophagus is approximately 18–25 cm long extending from the upper esophageal sphincter to the lower esophageal sphincter. The length of the esophagus correlates with an individual's height and it is usually longer in men than in women.

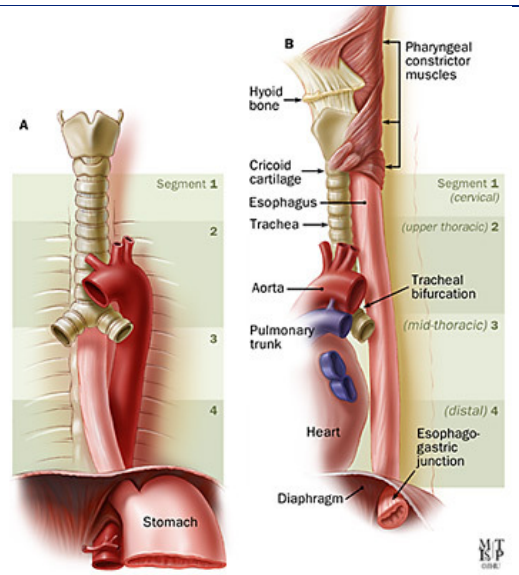

Figure 4. Normal anatomy of the esophagus in relation to the trachehobronchial tree; A, anterior view; B, lateral view.

The esophagus transports food from the mouth to the stomach in a caudad direction and prevents the retrograde movement of gastric or esophageal contents. It is a hollow tube closed at the upper end by the upper esophageal sphincter and at the lower end by the lower esophageal sphincter. The lumen is lined with squamous mucosa consisting of longitudinally oriented muscle fibers (muscularis mucosae). It is connected to the muscularis propria by connective tissue fibers of the submucosa. The muscularis propria has two layers: an inner circular muscle layer with circumferential fibers and an outer longitudinal layer with fibers oriented along the axis. The muscle in the muscularis mucosae is smooth along the length of the esophagus, whereas the muscularis propria is composed of striated muscle in the most proximal portion. Smooth and striated muscle meet in the middle third of the esophagus. A rich network of intrinsic neurons capable of producing secondary peristalsis is found in the submucosa and between the circular and longitudinal muscle layers. This network communicates to the central nervous system via the vagi, the adrenergic ganglia, and the celiac ganglia.

The lymphatic supply of the esophagus is extensive and consists of a dense network of lymphatic vessels deep within the mucosa and submucosa. These communicate freely with lymphatic channels in the muscular layers and those that reach the periesophageal lymph nodes (Figure 5).

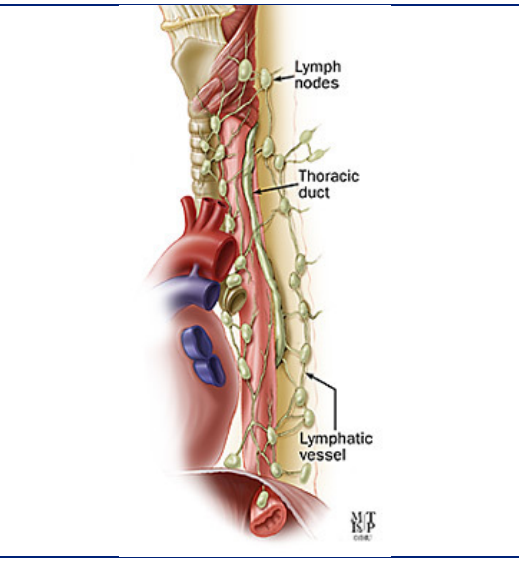

Figure 5. Esophagus in relation to tracheobronchial tree and lymphatic drainage.

© Copyright 2001-2013 | All Rights Reserved.
600 North Wolfe Street, Baltimore, Maryland 21287

Esophageal Cancer: Causes

Genetic Factors

The role of genetic factors in esophageal cancer is not clear. There is no incidence of this malignancy in family members of patients with this disease, with the exception of families with tylosis, a rare autosomal-dominant genetic condition. It is postulated that the strong male predominance in esophageal carcinoma may be attributable to environmental factors.

Environmental Factors

Alcohol
A number of studies have demonstrated a dose-response relationship between consumption of alcohol and squamous cell esophageal cancer. The type of beverage consumed may also play a role. In a recent study in South Carolina, home-brewed liquor ("moonshine") was linked to an unusually high incidence of this neoplasm.

Cigarette Smoking
Several studies have demonstrated an association between cigarette smoking and increased risk of squamous cell esophageal cancer. Like alcohol, the risk increases with increased consumption. It has been suggested that smoking, along with high alcoholic beverage consumption, increases the risk of developing esophageal cancer. The relative risk of cigarette smoking has been difficult to ascertain because a majority of patients with esophageal cancer who smoke cigarettes also drink an excessive amount of alcohol.

Nutrition
Iron, riboflavin, and vitamin A deficiencies have been associated with increased incidence of squamous cell esophageal cancers, although direct evidence for their role is lacking. Low consumption of each of the following food groups – fresh and frozen meat, fish, fruits and vegetables, and dairy and egg products – was associated with increased incidence of this form of cancer. The lack of a varied diet appears to have a convincing association with the development of esophageal carcinoma. Ingestion of food at very elevated temperatures and the lack of water intake during meals may also be contributory.

Socioeconomics
Generally, esophageal squamous cell carcinoma is a disease of lower socioeconomic groups. Lower socioeconomic status is associated with higher incidence worldwide.

Uncommon Exposures and Diseases

Although there are unusual or rare causes of esophageal cancer, they are worth mentioning because of their epidemiological implications. Achalasia, radiation exposure to the esophagus, and lye ingestion are all associated with an increased risk of squamous cell esophageal cancer as well as head and neck cancer, diets high in pickled vegetables, iron deficiency anemia and dysphagia. Celiac disease has also been specifically associated with esophageal cancer and more generally with other forms of gastrointestinal cancer.

Barrett's Esophagus

Barrett's esophagus, a specialized intestinal-type metaplasia in the tubular esophagus, is a well-established risk factor for adenocarcinoma of the esophagus. The risk of adenocarcinoma in Barrett's esophagus is estimated to be 30–45 times higher than in the normal population (Figure 6). Though the median age of incidence and the high prevalence in men is similar to squamous cell carcinoma, this form of esophageal cancer is more than 3 times higher in white men than black men and the male-to-female ratio is 7.6 in whites and 14.0 in blacks.

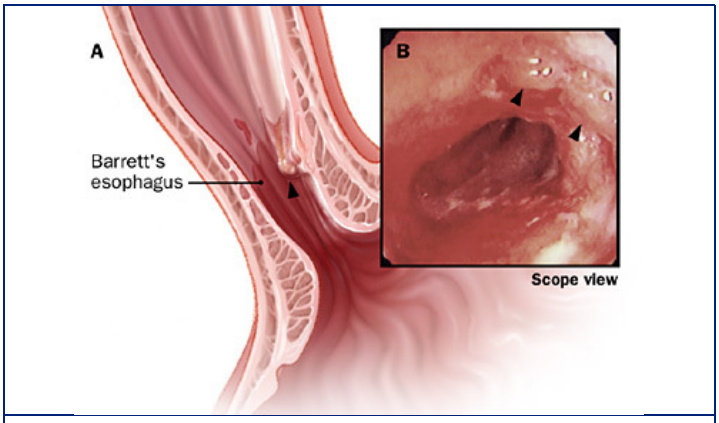

Figure 6. Endoscopic view of early adenocarcinoma in Barrett's esophagus.

Barrett's esophagus is characterized by replacement of normal squamous epithelium by mucosa with goblet cells and a villiform surface configuration that resembles intestinal mucosa. Controversy exists regarding the relative risk of short- vs. long-segment Barrett's esophagus; evidence indicates that the short-segment type confers lower risk of esophageal and gastric cardia adenocarcinoma compared to long-segment Barrett's esophagus (Figure 7).

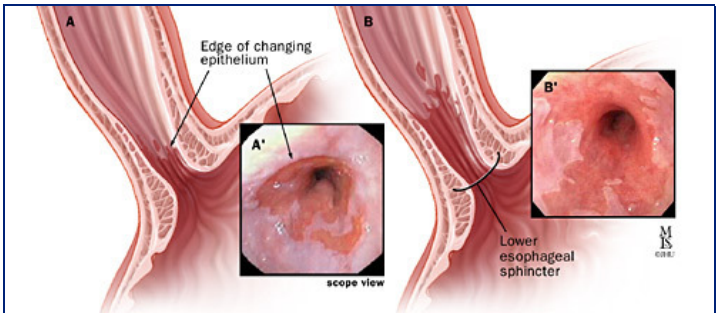

Figure 7. A, Short segment Barrett's esophagus; B, long segment Barrett's esophagus; A',B', corresponding endoscopic views.

Gastroesophageal reflux disease, defined as heartburn and/or regurgitation occurring at least once a week, has been directly linked with a marked increase in the risk for esophageal cancer. Gastroesophageal reflux has been linked to adenocarcinoma because of its predisposition to Barrett's esophagus (considered to be the precursor lesion). Recent studies have suggested the more frequent, more severe, and longer lasting the symptoms of reflux, the greater the risk for adenocarcinoma of the esophagus.

© Copyright 2001-2013 | All Rights Reserved.
600 North Wolfe Street, Baltimore, Maryland 21287

Esophageal Cancer: Diagnosis

Overview

Diagnostic evaluation of the patient with esophageal carcinoma has a two-fold purpose. First, it confirms the diagnosis through the use of radiography and/or endoscopy with biopsy and cytology. Second, diagnostic evaluation determines the disease stage for initiation of appropriate therapeutic measures.

Noninvasive Diagnosis

Barium contrast radiography is one of the diagnostic tests for the evaluation of dysphagia and the associated symptoms of esophageal cancer. Though endoscopy is considerably more sensitive for detection of esophageal cancer, double-contrast barium esophagrams can detect early esophageal carcinomas. The diagnostic accuracy of the double-contrast barium esophagram is 70%. This radiological technique is capable of documenting stricture length, diameter, location, and contour. Early erosive carcinoma may demonstrate loss of normal smooth mucosal pattern, ulcerations and wall irregularities, or stiffness. Intraluminal filling defects and elevated carcinomas may be detected. Advanced disease presents as polypoid intraluminal masses and loss of esophageal distensibility in the presence or absence of luminal narrowing (Figure 8).

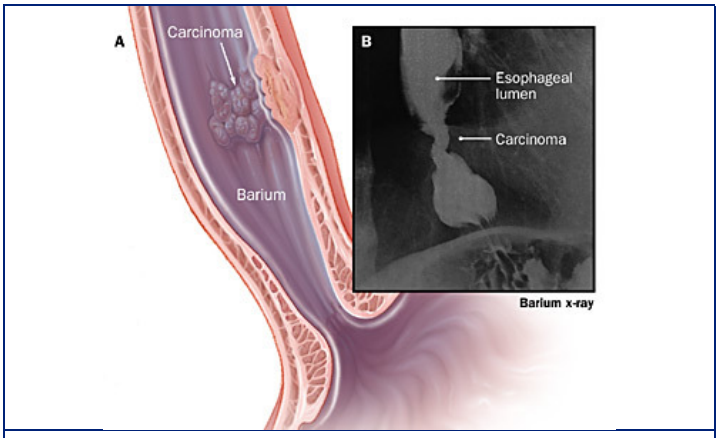

Figure 8. A, Esophageal carcinoma; B, corresponding barium swallow x-ray.

Endoscopic Diagnosis

Upper Endoscopy

Upper endoscopy involves the examination of the lining of the esophagus, stomach, and first part of the small intestine with a flexible endoscope. Gastrointestinal endoscopy allows the physician to visualize and biopsy the mucosa of the upper gastrointestinal tract. During these procedures the patient may be administered a pharyngeal topical anesthetic that helps to prevent gagging. Pain medication and a sedative may also be administered prior to the procedure. The patient is placed in the left lateral position and an endoscope, a thin, flexible, lighted tube is passed through the mouth and pharynx and into the esophagus. The endoscope transmits an image of the esophagus to a monitor visible to the physician (Figure 9).

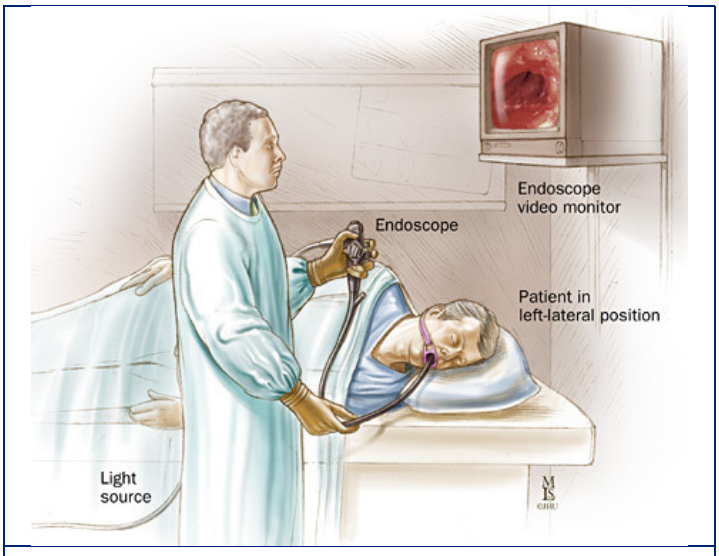

Figure 9. Room set-up and patient positioning for endoscopy.

Endoscopy with biopsy is the primary method for diagnosing esophageal cancer. With this technique, biopsies may be directed, under endoscopic guidance, to abnormal areas for sampling and tissue diagnosis. Endoscopic brush cytology can also be helpful in obtaining a histological diagnosis, particularly in squamous cell carcinomas, which may yield indeterminate or nondiagnostic mucosal biopsies. Brush cytology is very useful in evaluating malignant-appearing strictures, particularly those that are nontraversable by the standard endoscope. The combination of endoscopic biopsy and brush cytology has the highest accuracy rate, close to 100%, in obtaining a histological diagnosis of esophageal cancer.

Endoscopic Ultrasonography (EUS)

Endoscopic ultrasonography (EUS) is a useful tool for the diagnosis of esophageal cancer. It is a highly technical, low-risk, diagnostic procedure that utilizes ultrasound to evaluate and diagnose digestive tract disorders. Endoscopic ultrasound allows imaging at close proximity and may detect subtle mucosal changes in the patient in whom other tests are nondiagnostic (Figure 10).

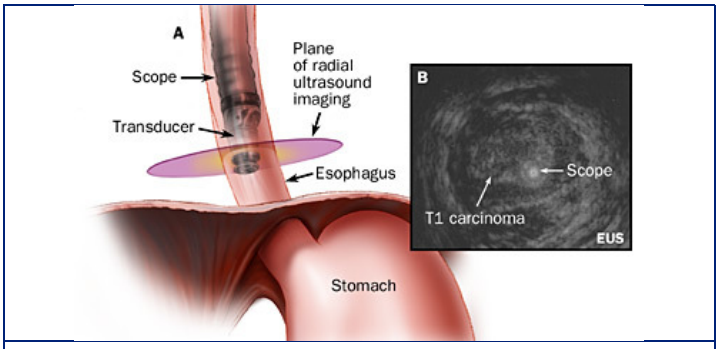

Figure 10. A, Radial scanning for esophageal carcinoma; B, corresponding endoscopic ultrasonography (EUS) image.

High-frequency endoscopic ultrasonography (EUS) may be helpful in directing endoscopic biopsy toward areas of endosonographic abnormalities in patients with Barrett's esophagus and high-grade dysplasia. A focal hypoechoic nodule within the superficial layers of the esophageal wall may indicate the presence of an occult carcinoma in Barrett's esophagus (Figure 11).

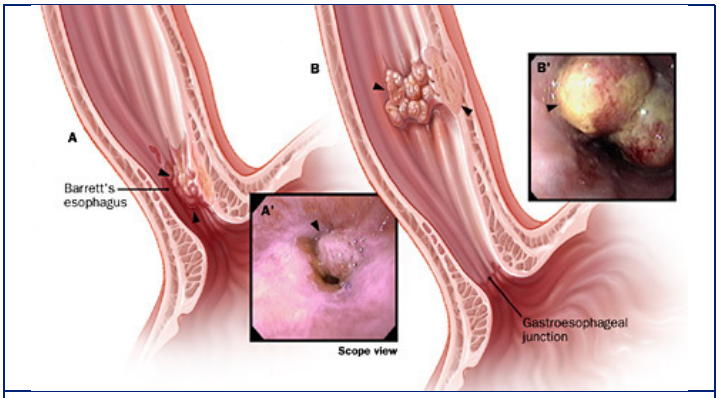

Figure 11. A, Adenocarcinoma; B, squamous cell carcinoma of the esophagus; A', B', corresponding endoscopic views.

Screening and Surveillance

The term "screening" is applied to diagnostic testing of asymptomatic at-risk individuals. “Surveillance" pertains to the diagnostic evaluation of individuals who have been identified as having an increased risk for a disease. In the United States, there are no existing guidelines or accepted methods for screening for esophageal cancer. There are, however, ongoing studies of screening in select high-risk groups.

Balloon Cytology

Outside the United States, in areas where esophageal cancer is highly prevalent (such as in China), screening is performed using transnasal abrasive balloon cytology. A mesh-covered deflated balloon is swallowed, and then the balloon is inflated and withdrawn. The cells on the balloon are smeared on slides, stained, and examined by light microscopy for dysplasia or cancer. Identification of positive results on balloon cytology requires endoscopy and biopsy (Figure 12). Balloon cytology has also been used in the United States for screening patients with Barrett's esophagus. However, the sensitivity for diagnosing high-grade dysplasia and cancer is only 80%.



Figure 12. Diagnostic cytology balloons.

Screening Endoscopy

Some physicians advocate the use of screening endoscopy to diagnose Barrett's esophagus and to detect early adenocarcinoma in high-risk, asymptomatic, middle-aged, white men with a history of gastroesophageal reflux disease (GERD) . However, this strategy has not been proven to be cost-effective and currently is not recommended as standard of care in all patients with a history of GERD.

On the other hand, patients with a diagnosis of Barrett’s esophagus are at increased risk for esophageal cancer, and the majority of physicians in the United States perform endoscopic surveillance in this group. Published guidelines from the American College of Gastroenterology (1998) exist on the management of Barrett's esophagus and include recommendations on endoscopic surveillance. In patients with no or low-grade dysplasia on prior endoscopic biopsy, these guidelines recommend increasing the surveillance from once a year to 3–6-month intervals.

The optimal endoscopic technique for surveillance upper endoscopy has not been proven. There is controversy regarding the type of biopsy forceps (standard vs. large-particle or "jumbo" biopsy), the technique (biopsy from four quadrants at standard intervals within the esophagus or purely at random), and the intervals between four-quadrant biopsy (every 1 or 2 cm).

Chromoendoscopy

Chromoendoscopy refers to the use of vital stains to identify abnormal mucosa. It has been used for esophageal cancer screening for many years. In patients who are at increased risk for squamous cell carcinoma, vital staining with Lugol's solution is performed at the time of upper endoscopy to aid in cancer detection. Lugol's staining involves the application of a solution that contains potassium iodide and iodine through a spray catheter. The dye stains the glycogen in normal squamous epithelium a dark brown color. Areas that are unstained, particularly those that are larger than 5 mm, are likely to be dysplastic or malignant and can be readily targeted for endoscopic biopsy. Smaller unstained areas (less than 5 mm) may be due to inflammatory change. The staining procedure is quick, technically easy to perform, and inexpensive. It has been shown to be very effective in diagnosing early squamous cell cancers that are not endoscopically evident in high-risk patients with a history of head and neck cancer or heavy alcohol and/or smoking exposure (Figure 13).

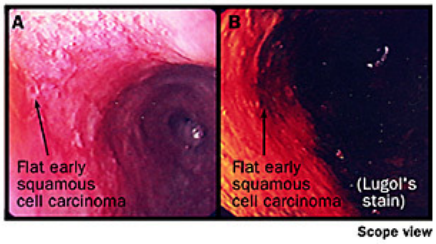

Figure 13. Endoscopic images; A, early squamous cell carcinoma; B, Lugol's stain.

Chromoendoscopy using methylene blue staining has not been studied as a screening method for patients with Barrett's esophagus. However, methylene blue-directed jumbo biopsy has been shown in a prospective randomized, sequential study to be more cost-effective than four-quadrant jumbo biopsy in the diagnosis of dysplasia and cancer in Barrett's esophagus. In-vivo and in-vitro studies have demonstrated that the finding of a moderate to marked heterogeneous staining pattern and/or focal lack of blue stain within a diffusely stained Barrett's esophagus, is highly suggestive of high-grade dysplasia or early invasive adenocarcinoma (Figure 14).

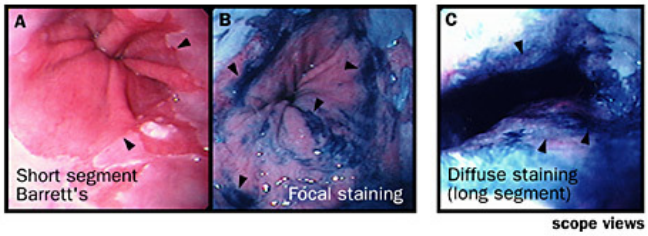

Figure 14. Endoscopic images; A, short-segment Barrett's esophagus; B, C, long-segment Barrett's esophagus with methylene blue stain.

Future Screening/Surveillance Techniques

Flow cytometry, molecular biomarkers, laser-induced fluorescence spectroscopy, and endoscopy may prove the accuracy of endoscopic surveillance for adenocarcinoma in Barrett's esophagus.

Staging

Staging is critical for the management of esophageal cancer. It stratifies treatment strategy into curative or palliative. It is also important for the evaluation of resectability in patients who are considered surgical candidates. Staging provides prognostic information, useful to physicians, patients, and families, to aid in management-related decisions in cases of advanced disease. Finally, staging can improve patient selection for neoadjuvant chemoradiation therapy (Figure 15).

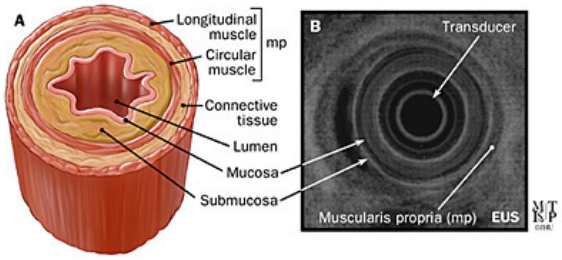

Figure 15. A, Normal anatomy of the esophageal wall; B, endoscopic ultrasonography (EUS) image.

The location of the esophagus in the posterior mediastinum and the proximity of the aorta and trachea also make diagnostic evaluation and staging more challenging compared to gastrointestinal organs in the abdomen. The location of the tumor in the esophagus also influences the feasibility of resection. Generally, tumors located at or above the tracheal bifurcation may not be as resectable in less advanced stages than those that are distal because of the contiguity with and early invasion of the tracheobronchial tree. In contrast, tumors located below the tracheal bifurcation are often resectable in advanced stages due to a more favorable anatomic location.

Staging procedures generally follow the TNM clinical classification system, which was fundamentally revised in 1987. The T stands for tumor depth of invasion, the N for regional lymph node metastasis, and the M for distant organ metastasis.

TNM Clinical Classification System

T	Primary tumor
T1	Primary tumor invading lamina propria or submucosa
T2	Primary tumor invading muscularis propria
T3	Primary tumor invading adventitia
T4	Primary tumor invading adjacent structures
Tx	Primary tumor cannot be assessed
N	Regional lymph nodes
N0	No regional lymph node metastasis (excluding celiac lymph nodes)
N1	Regional lymph node metastasis (excluding celiac lymph nodes)
Nx	Regional lymph nodes cannot be assessed
M	Distant metastasis
M0	No distant metastasis
M1	Distant metastasis: hepatic metastasis, peritoneal dissemination, or lymph node metastasis at the celiac trunk (pleural and peritoneal dissemination being rare)
Mx	Distant metastasis cannot be assessed

TNM Stage Grouping

Stages	Grouping
Stage I	T1, N0, M0
Stage IIA	T2, N0, M0; T3, N0, M0
Stage IIB	T1, N1, M0; T2, N1, M0,
Stage III	T3, N1, N0; T4, N0, M0; T4, N1, M0
Stage IV	Any T, any N, M1

There has been some confusion related to the terms intraepithelial cancer or carcinoma in-situ. Cancer is now only diagnosed when there is clearly invasion of cells beyond the muscularis mucosa. Marked cellular morphological changes that may be present only in the mucosal layer are considered high-grade dysplasia instead of carcinoma.

The risk of regional lymph node metastasis is relatively high (33–45%) even in early squamous cell esophageal cancer that penetrates to the submucosal layer. In contrast, the risk for regional lymph node metastasis is much lower for lesions that are confined to the mucosa. Hence, lymph node staging and tumor depth of invasion have important implications for therapy and prognosis.

Clinical staging begins with a history, physical examination, and blood tests focused toward detecting metastasis to the supraclavicular or cervical lymph nodes, abdominal wall, liver, and lungs. Chest x-ray can be helpful in detecting metastatic disease to the lungs that appears as multiple bilateral pulmonary nodules. Modern cancer staging generally involves a CT scan of the chest and abdomen with intravenous and oral contrast in addition to EUS. EUS is indicated only if there is no evidence of distant metastasis (Figure 16).



Figure 16. Diagnostic approach to the patient with esophageal cancer.

Radiological Staging

Computed Tomography (CT)
CT is the modality of choice for staging distant metastasis. It provides information regarding T stage on the basis of wall thickness and contour. CT scanners and scanning techniques, however, cannot provide a layered image of esophageal wall even with the most modern equipment (Figure 17).

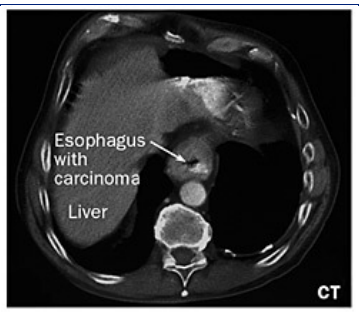

Figure 17. CT scan of esophageal cancer.

Generally, esophageal wall thickness greater than 5 mm is considered abnormal. Stage TI or T2 disease is diagnosed when wall thickness is greater than 5 and less than 15 mm thick. A T3 cancer is diagnosed if the thickness is greater than 15 mm. Local infiltration of adjacent organs (T4) is diagnosed by the presence of mass effect or loss of the normal fat planes. CT is, therefore, helpful in diagnosing local mediastinal invasion. The diagnosis of tracheobronchial invasion is more accurate than aortic invasion. However, resectability remains difficult to predict by CT scan because most symptomatic esophageal tumors are advanced at the time of diagnosis; consequently, T staging is high. Regional lymph nodes are diagnosed based on the maximal diameter; nodes larger than 10 mm are generally considered

to be metastatic.

Magnetic Resonance Imaging (MRI)
In general MRI has not been routinely recommended for esophageal cancer staging because it is no better than CT.

Positron Emission Tomography (PET) Scan
Several studies suggest positron emission tomography (PET) scanning with18F-fluorodeoxyglucose may be superior to conventional imaging for staging esophageal cancer, especially in the detection of occult distant metastases. PET scans were prospectively compared with CT scans in 91 patients with esophageal cancer. They detected significantly more distant metastases when compared to CT (84% vs. 63% accuracy, respectively) however, sensitivity was only 67% compared with minimally invasive staging. Other studies have confirmed the advantage of PET over CT scan for staging distant metastasis.

Endoscopic Staging

Endoscopic Ultrasonography (EUS)

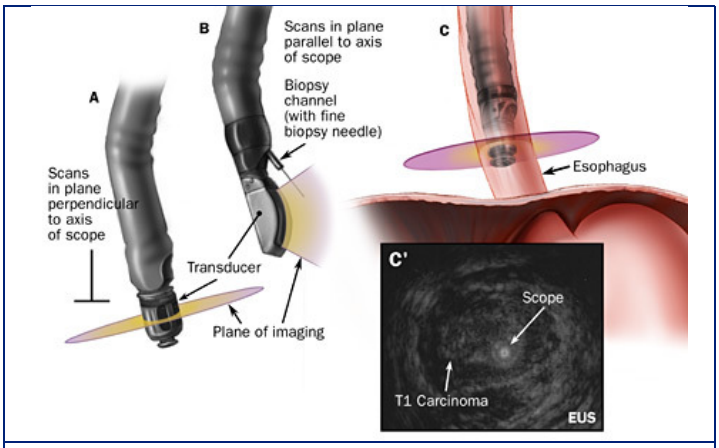

Figure 18. Technique for esophageal scanning; A, radial ultrasonography scope; B, linear endoscopic ultrasonography scope; C, positon of the scope in the esophagus; C', corresponding EUS image.

Standard EUS (S-EUS) (Figure 18) combines endoscopy with high-frequency ultrasound (7.5 and 12 MHz) within the esophageal lumen and provides high-resolution, detailed images of the tumor, the esophageal wall, and adjacent structures. Generally, the higher the frequency of imaging, the higher the image resolution, and the lower the depth of penetration. Radial scanning EUS provides a circumferential or cross-sectional view of the esophagus. The typical EUS image of the esophageal wall has a five-layered appearance that has been histologically correlated to distinct layers. Esophageal cancers appear dark or hypoechoic. Consequently, EUS can precisely determine the depth of invasion based on the location and appearance of the outer tumor border (Figure 19).

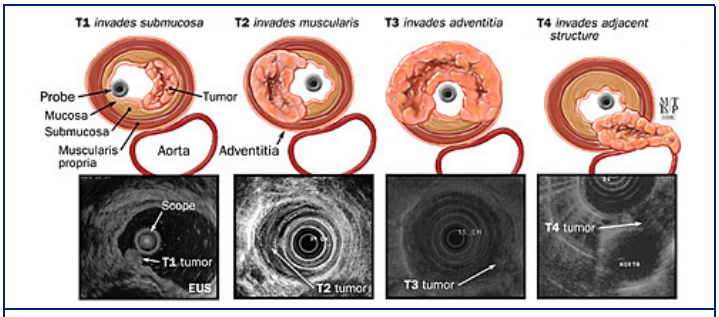

Figure 19. Esophageal carcinoma staging progression from T1 to T4 with corresponding endoscopic ultrasonography images.

T4 cancers may show aortic invasion (loss of hyperechoic interface or wraps around anterior or lateral circumference), pleural invasion (loss of bright pleural interface echoes and/or pleural fluid), or pericardial invasion (loss of bright pericardial interface, tumor pseudopodia). Invasion into the air-containing trachea or major bronchi is more difficult to diagnose with EUS; therefore, many cancer centers advocate routine bronchoscopy for all tumors at or proximal to the tracheal bifurcation. T4 cancers are generally considered unresectable, unless neoadjuvant therapy results in downstaging.

Lymph nodes are evaluated on the basis of several criteria including echogenicity, border, homogeneity, size, and shape. These criteria are subjective and subject to variability in interpretation and error. When characteristic features of a malignant lymph node are present, the positive predictive value and accuracy are very high. Malignant lymph nodes are generally hypoechoic, sharply demarcated (distinct border), homogeneous, and roundish.

Benign lymph nodes are usually hyperechoic, with an indistinct or fuzzy border, heterogeneous, and oval, draping, triangular, or elongated. Benign inflammatory lymph nodes may often be seen in the mediastinum, particularly in the subcarinal area, in certain regions of the United States (Figure 20).

EUS Feature	Malignant	Benign
Size	> 1.0 cm	< 1.0 cm
Echogenicity	Hyoechoic	Hyperechoic
Margins	Sharp	Fuzzy
Shape	Round or oval	Elliptical, "draping", triangular

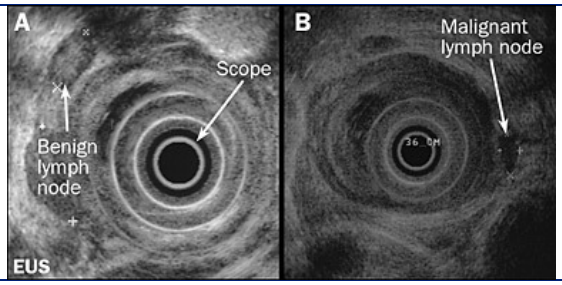

Figure 20. Endoscopic ultrasonography (EUS) images; A, benign; B, malignant lymph nodes.

Lymph nodes may be classified as malignant or benign based on fulfillment of the above criteria. Otherwise, the lymph node will be called indeterminate.

When compared with CT scan, EUS provides the most accurate locoregional staging of depth of invasion (T) and regional lymph node metastasis (N). The accumulated data from numerous studies indicate the overall accuracy of EUS for staging tumor depth of invasion (T) is 85%, compared to surgical pathology. The accuracy for staging regional lymph node metastasis (N) is about 75%. The reason for lower accuracy of N staging is the inability of EUS alone to differentiate malignant from benign lymphadenectomy.

Higher T stage accuracy is achieved with higher ultrasound frequencies (15, 20, and 30 MHz) using a catheter probe that can be passed through the accessory channel of the endoscope (miniprobe or C-EUS) (Figure 21). C-EUS has the added advantages over S-EUS of technical ease of use, short imaging time, and lack of compression effect on small tumors.

Figure 21. Endoscopic ultrasonography probes; A, miniprobe; B, miniprobe with balloon sheath; C, blind esophagoprobe.

Imaging the entire length of tumor and celiac axis provides the greatest staging accuracy though malignant strictures may not be traversable (up to 25% of cases). Although most stenosing cancers are advanced, bulky T2 tumors are not rare (11–17%), particularly exophytic adenocarcinomas. The options for EUS staging of nontraversable tumors include: 1) careful dilatation prior to EUS, 2) use of a "blind" esophagoprobe (which is exactly like the standard radial scanning echoendoscope, minus the optics) over a guide wire, 3) use of a catheter ultrasound probe, or 4) imaging with the echoendoscope at the top of a stricture. The last option is the least preferred because it may understage locally invasive tumors.

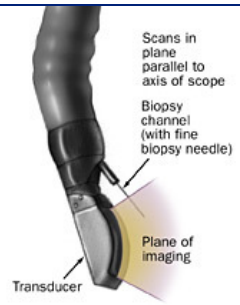

Figure 22. Linear array echoendoscope.

Linear array EUS enables ultrasound imaging parallel to the plane of the endoscope and transducer (Figure 22). A needle can be passed through the accessory channel of the endoscope and visualized in real time as it is directed through the esophageal wall and into mediastinal lesions. EUS-guided fine-needle aspiration (FNA) (Figure 23) is performed in many large medical centers as part of routine esophageal cancer staging. The main clinical utility of EUS-FNA is cytological diagnosis of regional and distant tumor metastasis, which can diagnose tumor stage and influence treatment decisions.

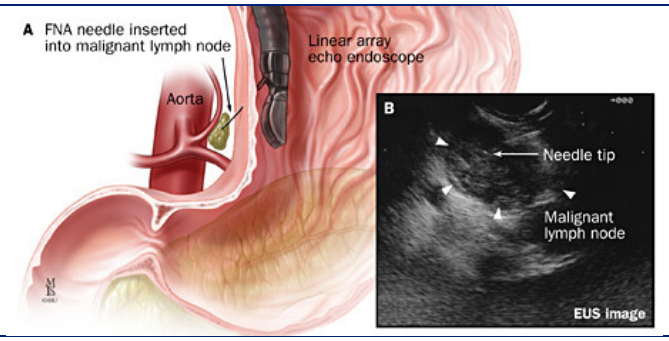

Figure 23. A, Technique of fine needle aspiration (FNA); B, corresponding endoscopic ultrasonography image.

EUS is not indicated for staging distant metastatic disease. If metastatic lesions in the liver, adrenal glands or celiac, perigastric, or periaortic lymph nodes are

visualized during EUS, Stage IV disease can be histologically documented by EUS-guided FNA.

EUS staging is best used prior to neoadjuvant chemoradiation therapy. This practice has become standard in most medical centers. Post-treatment fibrosis and inflammation may be indistinguishable from primary tumor in the wall or lymph nodes.

Bronchoscopy Staging

Bronchoscopy is routinely performed in some medical centers for evaluation of cancers in the cervical and proximal esophagus. EUS is unable to accurately evaluate invasion into the tracheobronchial tree because these structures contain air. Other centers rely solely upon the CT scan, which shows features of encasement, compression, or displacement of the trachea or major bronchi.

Surgical / Laparoscopic Staging

Routine laparoscopy has been advocated as part of the staging of cancers of the esophagus and esophagogastric junction (Figure 24). Laparoscopic ultrasonography and peritoneal lavage are also performed at the time of laparoscopy. Laparoscopy can diagnose small occult liver and intraperitoneal metastases that are not evident on CT scan with resultant upstaging of the cancer; these findings may alter the treatment strategy. Additional information obtained at laparoscopy can prevent unnecessary surgery in approximately 5–19% of patients. Laparoscopy appears to be most beneficial in patients with adenocarcinoma of the distal esophagus or cardia in whom there is significant liver metastases and peritoneal tumor spread (22% and 25%). Laparoscopy has not been shown to be as useful in squamous cell carcinomas.

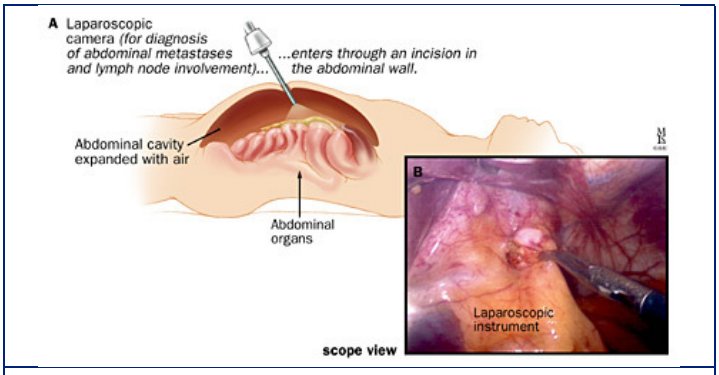

Figure 24. A, Technique for laparoscopic staging of metastasis; B, laparoscopic view.

In the absence of obvious distant metastasis, laparoscopy can increase the accuracy of locoregional staging by enabling biopsy of celiac and perigastric lymph nodes. Our experience has found jejunal feeding tube placement at the time of laparoscopic staging useful prior to initiation of adjuvant chemoradiation. The feeding tube helps maintain enteral support in patients with cachexia and/or high-grade esophageal strictures or those patients who develop nausea, vomiting, and anorexia during chemotherapy.

© Copyright 2001-2013 | All Rights Reserved.
600 North Wolfe Street, Baltimore, Maryland 21287

Esophageal Cancer: Therapy

Overview
Tumor stage generally determines the goal of treatment–to cure, prolong survival, or palliate cancer-related symptoms. Selection of therapy is contingent upon the medical condition of the patient, patient preferences, and available professional expertise. Unfortunately, because most esophageal cancers present in a late stage (tumors involving the submucosa tend to disseminate), the overall cure rate is low. Curative intent is usually reserved for localized tumors, Stage 0, I, or IIA (Tis, T1, T2, T3 with no regional lymph node metastasis). Prolongation of survival is usually the treatment goal for Stage IIB and III. However, a significant number of these patients with complete response to neoadjuvant therapy have prolonged disease-free survival but relatively low cure rates. Palliative treatment is appropriate for metastatic disease (Stage IV) and surgery is usually deferred in favor of endoscopic methods to treat malignant dysphagia or fistulous disease.

It is important to note that nearly all the major published trials on esophageal cancer therapy for localized or advanced cancer did not use or require EUS for staging. Furthermore, the largest trials of multimodality therapy do not distinguish Stage I or IIA from IIB or III in the results. Therefore, it is impossible to directly compare the results of radiation, chemotherapy, or multimodality therapy due to heterogeneity in staging based on CT scans alone or CT and EUS.

Therapy for Localized Disease
Several treatment options exist for localized esophageal cancer (any T stage, without regional lymphadenectomy). Traditionally, surgery is the treatment of choice in patients with early disease. However, endoscopic therapy has been shown to be a safe and effective alternative in patients with T1 cancer and multiple medical comorbidities. Chemoradiation therapy is also a suitable alternative in this high-risk group for whom surgery is not the best option.

Surgery
Surgical resection is highly curative in early-stage esophageal cancer, but survival rates decline when tumors invade beyond the submucosa or are more advanced than Stage I. The most common surgical procedures performed are transthoracic esophageal resection using the right- or left-chest approach or transabdominal resection by blunt dissection. The esophagus is replaced with a new esophagus constructed from the remaining stomach pulled up into the thoracic cavity or neck. The colon or jejunum can also be used for interposition if the stomach is not a suitable conduit (Figure 25).

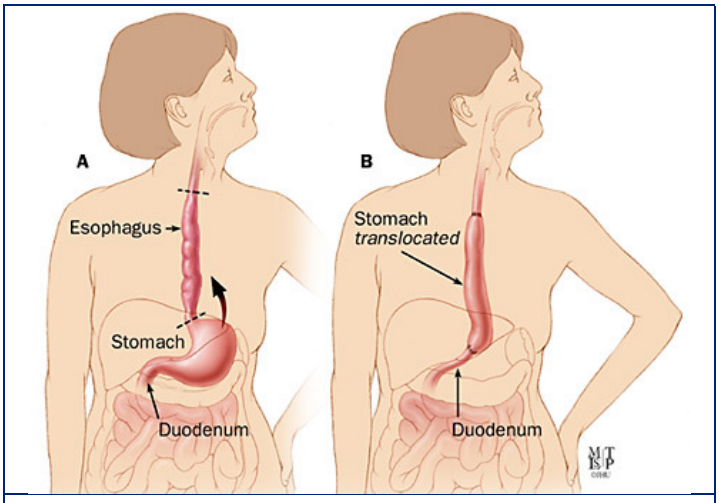

Figure 25. Technique for transhiatal esophagectomy; A, removal of the esophagus; B, translocation of the stomach.

Survival, local recurrence, morbidity, or mortality data are not significantly different for the two types of esophageal resections. The mortality rates for this procedure have decreased over the years from 10 to 3%. The postoperative morbidity, including anastomotic leaks, has also declined over the last 2 decades. Generally, outcomes from this surgery are improved due to improved perioperative care and surgical techniques.

More aggressive surgical resections have been performed to improve survival. However, it is uncertain whether the en-bloc resection of the esophagus with adjacent pericardium, diaphragm, azygous vein, and thoracic duct or extended cervical lymph node dissection improve overall survival. These operations have significantly increased morbidity, such as recurrent laryngeal nerve injury and chylothorax. Multimodality therapies have shown improvement in overall survival and are currently the recommended treatment when possible.

Radiotherapy
Radiation is another approach to a curative treatment for localized disease. The ideal dosage and timing of radiotherapy have not been fully established. There is little data on the safety and efficacy of brachytherapy or external beam radiotherapy alone for adenocarcinoma of the esophagus. Limited published data from Japan on radiation therapy for superficial squamous esophageal cancer suggest that it can result in overall survival rates of about 38.7%, as well as disease-specific 5-year survival rates of 71%. The complication rate was 15%, particularly in those with intraluminal -radiation therapy. Though there is some response to radiation therapy in "curative" doses, cancers may recur within a short time (3 months) and 3-year survival rates are low.

Radiation Plus Chemotherapy
Some studies have shown that the addition of chemotherapy (cisplatin and 5-fluorouracil [5-FU]) to radiotherapy improved local recurrence rate (65–44%) and improved 2-year survival from 10% to 38%, prolonging median survival by 4 months.

Chemotherapy Plus Surgery
In a multicenter trial, patients with Stage I–III disease were treated with either surgery alone or chemotherapy followed by surgery. A study by David Kelsen and colleagues demonstrated no benefit of preoperative cisplatin 5-FU for either squamous cell or adenocarcinoma of the esophagus compared to surgery alone when analyzing local recurrence and survival.

Chemoradiation Plus Surgery
In a large Phase III study of multimodal therapy (chemoradiation using cisplatin 5-FU followed by surgery) vs. surgery alone, Walsh and colleagues showed that the former is superior for patients with resectable adenocarcinomas. The survival advantage was evident at 3 years. Total parenteral nutrition or enteral nutrition through a percutaneous endoscopic gastrostomy (PEG) or jejunostomy (PEJ) tube can provide adequate nutritional support during adjuvant therapy.

Endoscopic Therapy for Localized Disease
There is accumulating data that endoscopic therapy is a safe, less invasive, and effective therapy for very early esophageal cancer. The candidates for endoscopic therapy are Stage 1 patients with tumors invading into the lamina propria (T1 mucosal) or submucosa (T1 submucosal) that do not have regional or distant metastasis. Patients with carcinoma in-situ or high-grade dysplasia can also be treated with endoscopic therapy. Submucosa cancers with increased risk of nodal metastases may not be as amenable to curative therapy.

The two forms of endoscopic therapy that have been used for Stage 0 and I disease are endoscopic mucosal resection (EMR) and mucosal ablation using photodynamic therapy , Nd-YAG laser, or argon plasma coagulation.

Endoscopic Mucosal Resection
Endoscopic mucosal resection has been advocated for early cancers (that is, those that are superficial and confined to the mucosa only) and has been shown to be a less invasive, safe, and highly effective nonsurgical therapy for early squamous cell esophageal cancer. Preliminary reports also suggest its safety and efficacy for early adenocarcinoma arising in Barrett's esophagus. The prognosis after treatment with endoscopic mucosal resection is comparable to surgical resection. This technique can be attempted in patients, without evidence of nodal or distant metastases, with differentiated tumors that are slightly raised and less than 2 cm in diameter, or in differentiated tumors that are ulcerated and less than 1 cm in diameter. The most commonly employed modalities of endoscopic mucosal resection include strip biopsy, double-snare polypectomy, resection with combined use of highly concentrated saline and epinephrine, and resection using a cap.

The strip biopsy method for endoscopic mucosal resection of esophageal cancer is performed with a double-channel endoscope equipped with grasping forceps and snare. After marking the lesion border with an electric coagulator, saline is injected into the submucosa below the lesion to separate the lesion from the muscle layer and to force its protrusion. The grasping forceps are passed through the snare loop. The mucosa surrounding the lesion is grasped, lifted, and strangulated and resected by electrocautery (Figure 26).

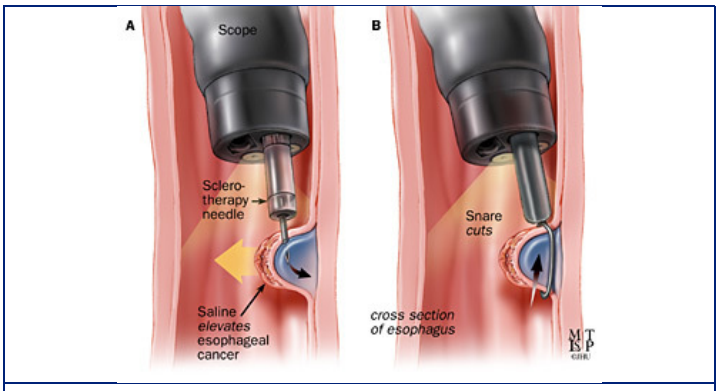

Figure 26. Technique of endoscopic mucosal resection with saline injection.

The endoscopic double-snare polypectomy method is indicated for protruding lesions. Using a double-channel scope, the lesion is grasped and lifted by the first snare and strangulated with the second snare for complete resection.

Endoscopic resection with injection of concentrated saline and epinephrine is carried out using a double-channel scope. The lesion borders are marked with a coagulator. Highly concentrated saline and epinephrine are injected (15–20 ml) into the submucosal layer to swell the area containing the lesion and elucidate the markings. The mucosa outside the demarcated border is excised using a high-frequency scalpel to the depth of the submucosal layer. The resected mucosa is lifted and grasped with forceps, trapping and strangulating the lesion with a snare, and then resected by electrocautery.

A fourth method of endoscopic mucosal resection employs the use of a clear cap and prelooped snare inside the cap. After insertion, the cap is placed on the lesion and the mucosa containing the lesion is drawn up inside the cap by aspiration. The mucosa is caught by the snare and strangulated, and finally resected by electrocautery. This is called the "band and snare" or "suck and cut" technique. The resected specimen is retrieved and submitted for microscopic examination for determination of tumor invasion depth, resection margin, and possible vascular involvement. The resulting "ulcer" heals within 3 weeks (Figure 27).

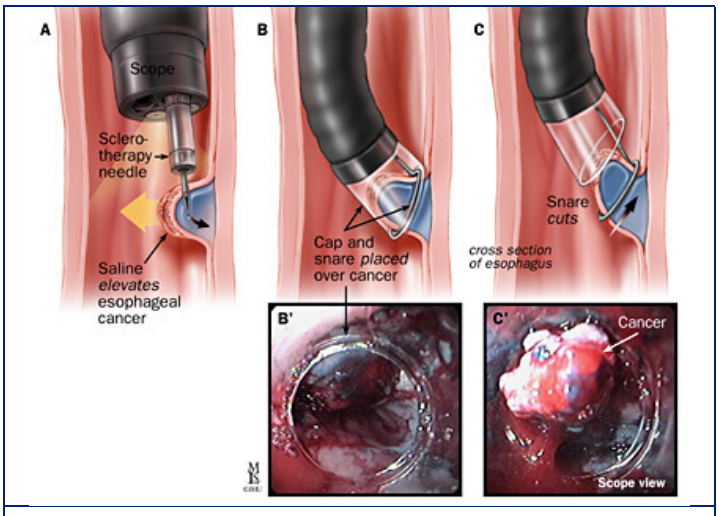

Figure 27. A-C, Technique of endoscopic mucosal resection using a clear cap; B', C', corresponding endoscopic views.

Although most lesions treated in the esophagus have been early squamous cell cancers, endoscopic snare resection can also be used to debulk or completely treat polypoid dysplastic or malignant lesions in Barrett's esophagus. In a preliminary report from Germany, EMR was performed as primary treatment or adjunctive therapy following photodynamic therapy for early adenocarcinomas in Barrett's esophagus. The "suck and cut" technique (with and without prior saline injection) was used as well as the "band and cut" technique. Although all tumors were resected without difficulty, 12.5% developed bleeding (which was managed successfully by endoscopic therapy). Eighty-one percent of the lesions were completely resected. The other lesions were also treated with other endoscopic techniques. While this report

suggests it is feasible to completely resect local, circumscribed, early adenocarcinomas arising in Barrett's esophagus, the relative safety and efficacy of EMR in conjunction with photodynamic therapy is unknown.

The major complications of endoscopic mucosal resection include postoperative bleeding and perforation and stricture formation. During the procedure, an injection of 100,000 times diluted epinephrine into the muscular wall, along with high frequency coagulation or clipping can be applied to the bleeding point for hemostasis. It is important to administer acid-reducing medications to prevent postoperative hemorrhage. Perforation may be prevented with sufficient saline injection to raise the mucosa containing the lesion. The "non-lifting sign" and complaints of pain when the snare strangulates the lesion are contrainidications of EMR. When perforation is recognized immediately after a procedure, the perforation should be closed by clips. Surgery should be considered in cases of endoscopic closure failure. The incidence of complication range from 0–50% and squamous cell recurrence rates range from 0–8%.

Photodynamic Therapy

Photodynamic therapy (PDT) using various photosensitizers is another highly promising endoscopic modality. PDT involves application of photosensitizer drug through the oral or intravenous route. There is preferential localization of the drug in high concentration in the dysplastic and malignant tissue. In the presence of oxygen, laser light at a specific wavelength activates the drug and results in a photochemical reaction that leads to selective tissue destruction. PDT has been applied to tumors in the esophagus, stomach, duodenum, bile duct, lung, and other sites of the body (Figure 28).

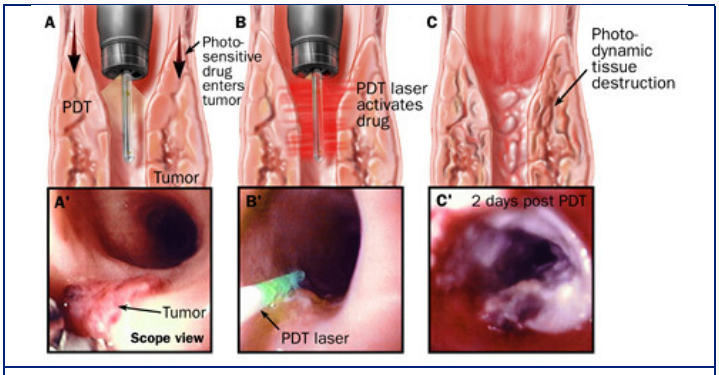

Figure 28. A-C, Technique of photodynamic therapy (PDT); A'-C', corresponding endoscopic images.

Photodynamic therapy and mucosal ablation have shown promising results in a variety of clinical trials in patients with esophageal cancer. Increasing numbers of studies have shown PDT to be safe and highly effective, especially for ablation of distinctive/specialized columnar epithelium and dysplasia in Barrett's esophagus. PDT has also shown clinical usefulness for the curative treatment of early squamous cell and adenocarcinomas of the esophagus. In addition, PDT has been shown to be effective for clinical use in early gastric cancer, colorectal cancer, and duodenal and ampullary tumors.

In a multicenter trial comparing PDT with Nd:YAG laser photoablation, PDT was shown to be as efficacious as laser thermal ablation for palliation of dysphagia in esophageal cancer. PDT was equal or better than Nd:YAG in terms of objective tumor response, especially for tumors located in the upper and lower third of the esophagus. The study concluded that PDT may be carried out with greater ease and is associated with fewer complications and better long-term results than ND:YAG laser therapy.

PDT should be considered an alternative treatment to open the esophageal lumen. PDT has been used successfully to open the esophageal lumen in patients with complete esophageal obstruction and in those with partially obstructing esophageal cancer. It has proven useful for high esophageal cancers, for those patients with prior radiation and chemotherapy, for some esophagogastric junction cancers, and as salvage therapy in patients in whom stents have failed due to migration or tumor ingrowth or overgrowth.

Although PDT appears quite promising in its therapeutic applications, it is not without adverse effects. Some patients have experienced dysrhythmias (which have responded to medical therapy) as well as nausea. Other adverse effects have included dysrhythmia, photosensitivity and stricture formation (which, in most cases, have responded to endoscopic dilation).

Therapy for Metastatic and/or Locally Advanced Disease

Multimodality therapy offers the best chance for prolonged disease-free survival in advanced esophageal cancer (Stage IIB and III). However, the morbidity is significant and the cure rate is low. Multimodal therapy followed by surgery offers the chance of complete response and improved survival in about 30–40% of patients. In nonsurgical candidates, radiation and chemotherapy alone may be an option. Palliative therapy can be offered to those patients in whom these therapeutic approaches are not an option or those patients with Stage IV or distant metastatic disease (Figure 29). Palliative esophagogastrectomy has been performed for severe obstruction but is associated with high morbidity and mortality.

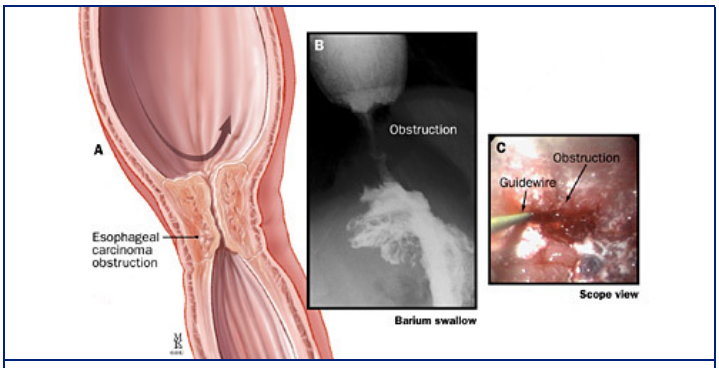

Figure 29. A, Near total obstruction from advanced esophageal cancer; B, barium swallow x-ray; C, endoscopic view.

The goal of palliation is the relief of symptoms and improvement of quality of life. The aim of palliative therapy is to maintain comfort, avoid inpatient hospital care, and minimize treatment-related side effects.

Chemoradiation Therapy for Palliation

Palliation is achieved in about 60–70% of those treated with chemoradiation therapy. Nutritional support with a percutaneous endoscopic gastrostomy (PEG) or jejunostomy tube (PEJ) is useful to maintain adequate hydration and nutrition during therapy.

Endoscopic Therapy for Palliation
Methods for treating malignant dysphagia.

Dilation	Passage of expandable balloon or wire-guided bougie
Sclerotherapy	Injection of a sclerosant like alcohol
Thermal Ablation	Coagulation of tumor using electrocautery
ND-YAG laser photoablation	Coagulation and vaporization of tumor using high energy laser
Stent	Placement of a hollow plastic tube or expandable metal stent
Photodynamic therapy	Injection of photosensitizing agent activated by low-power laser light, resulting in selective tumor necrosis

Dilation involves passage of a through-the-scope expandable balloon or wire-guided polyvinyl bougies with fluoroscopic assistance through the malignant stricture. This treatment results in immediate expansion of the luminal diameter and often enables brief improvement in swallowing. Unfortunately, the effect of dilation usually lasts only for days. Dilation needs to be repeated at variable lengths of time or another method of palliation performed for longer-lasting treatment of dysphagia (Figure 30).

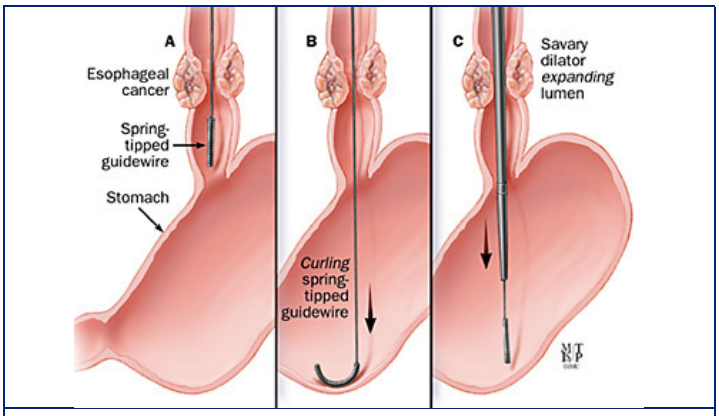

Figure 30. A-C, Technique of esophageal dilation with Savary dilator.

Sclerotherapy is the least expensive of the endoscopic ablative techniques. It involves injection of a chemical, usually alcohol, directly into the tumor using a similar technique for treatment of esophageal varices. The disadvantage of alcohol injection into tumor is the possibility of injury to normal tissues and perforation due to tracking of the sclerosant along tissue planes.

Thermal ablation involves use of monopolar or bipolar electrocautery. Typically, a probe is passed into the area of the tumor and the resulting heat energy causes coagulation of tumor tissue on the surface.

ND-YAG laser photoablation involves application of high-power laser light that results in coagulation and vaporization of tumor. The application of the laser energy may be technically difficult and require multiple sessions of laser application and debridement of necrotic tissue to achieve a satisfactory improvement in the stricture. This perforation rate may be as high as 7%. The palliative effects last approximately 4–6 weeks and treatments may need to be repeated to keep the lumen patent.

Esophageal stenting is the treatment of choice for tracheoesophageal fistulas. Covered metal stents successfully cover the fistulous opening and allow immediate improvement of coughing in most cases. In the past, plastic hollow tubes were placed in malignant strictures. However, these have been associated with up to a 15% risk of perforation. Currently, expandable metal stent is preferred because it is technically easier to insert and has a lower rate of acute complications. There are a variety of metal stents available. A metal stent may be covered with a plastic membrane that decreases the likelihood of tumor ingrowth. However, late complications (20–40% of cases) such as tumor overgrowth, stent migration, fistulization, and bleeding can occur. The likelihood of complications from stents is higher in patients who have undergone prior chemoradiation therapy. Furthermore, airway compression and foreign body sensation or pain can occur when stenting proximal esophageal tumors. Tumors that are near or involve the cricopharyngeus cannot be successfully stented. Stenting of distal esophageal cancers that involve the gastroesophageal junction may result in significant reflux or ulceration in the stomach from the ends of the wire stent. Food impaction can cause acute dysphagia unless the patient modifies his or her diet and/or is counseled about the importance of thoroughly chewing food. Post-stent pain can be very significant, requiring narcotic medications in many patients (Figure 31).

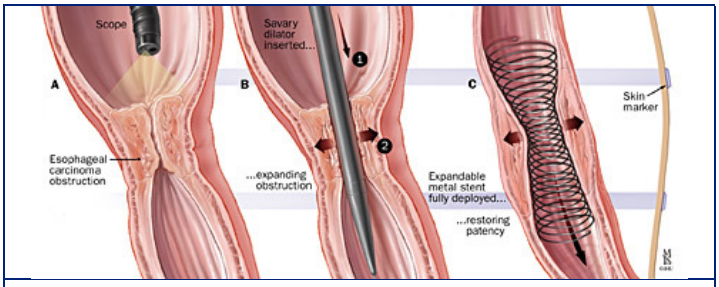

Figure 31. A-E, Dilation of tight stricture with placement of an expandable metal stent.

Photodynamic therapy (PDT) involves the systemic injection of a photosensitizing agent, such as porfimer sodium (Photofrin). The drug preferentially collects in high concentrations in tumor tissue relative to normal tissue. About 40–50 hours after injection, a low-power laser light is applied during an endoscopic procedure through a diffuser fiber passed through the accessory channel of the endoscope. The tumor exposed to red light undergoes necrosis due to the resultant photochemical reaction. The depth of treatment is about 5 mm (the penetration depth of red light into tissue). The chance of perforation is significantly less with PDT than ND:YAG laser therapy. PDT can be performed before or after chemoradiation therapy. It can also be used to treat tumor ingrowth or overgrowth in patients treated with a stent as well as complete obstruction by tumor. The disadvantage of PDT is the long duration of photosensitivity (4-6 weeks) due to the retention of the drug in the skin.

There is a risk of sunburn reaction (about 10%), which may be quite severe, depending on the duration and intensity of exposure and the timing of exposure (Figure 32).

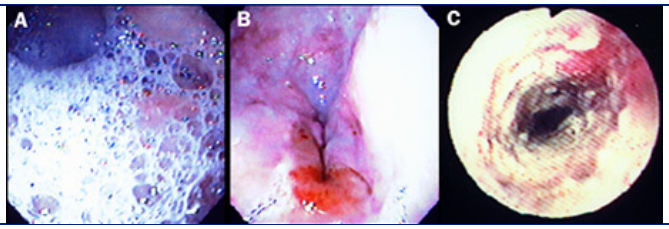

Figure 32. Endoscopic views of esophageal cancer; A, B, before therapy; C, after photodynamic therapy.

© Copyright 2001-2013 | All Rights Reserved.
600 North Wolfe Street, Baltimore, Maryland 21287